

Brain: Miscellaneous

Arachnoid Cyst

Arachnoid cysts are congenital CSF collections that are almost always asymptomatic. They are seen as incidental findings on CT and MRI scans, although they can be quite large and appear to have mass effect. Rarely arachnoid cysts do cause symptoms and require surgery.

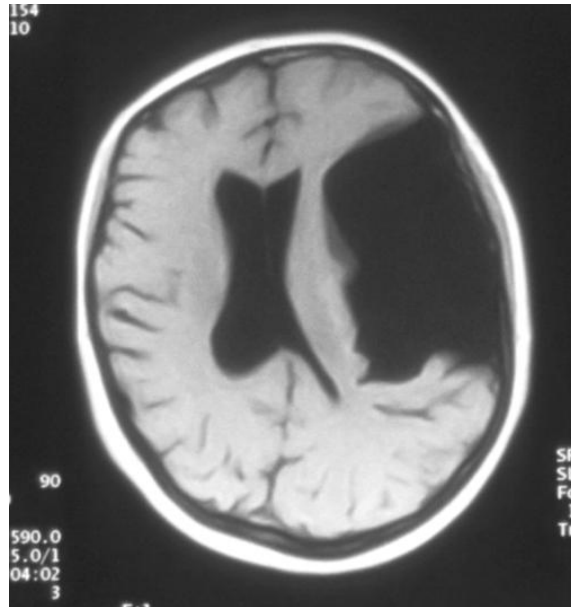


Figure 16: Arachnoid Cyst.