

Neoplasms (Tumors) of the Spine

Benign Neoplasms

Benign tumors of the spine are relatively rare. The most common are **meningiomas**, which are from the dura (actually the arachnoid), and **schwannomas** (Figure 9) and **neurofibromas** which arise from the nerve sheath (similar to dura) of the nerve roots.

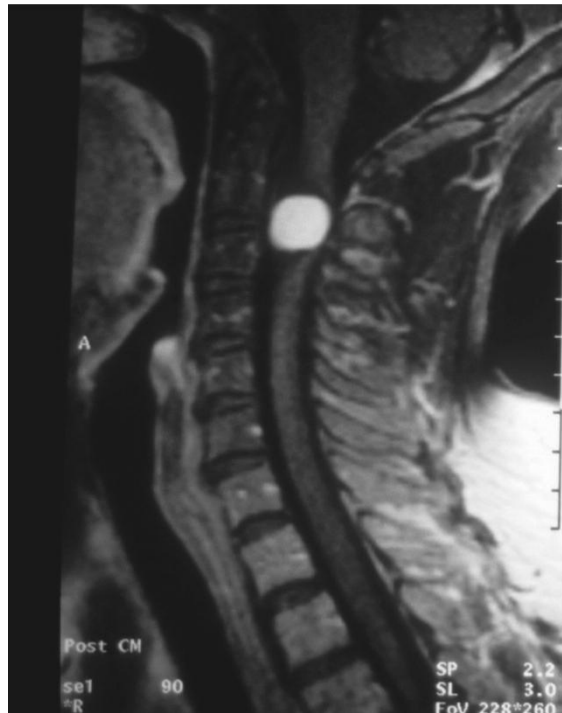


Figure 9: Mid-sagittal MRI showing a large schwannoma (white) in the upper cervical spine.

There are many other benign neoplasms that occur in the spine. A partial list of benign tumors that develop from the various structures of the spine are as follows:

- Bone chordoma, Langerhan's cell histiocytosis (LCH),
aneurysmal bone cyst (ABC)
- Dura and neural coverings schwannoma, neurofibroma, meningioma

Benign neoplasms do not invade surrounding tissues nor spread to distant sites like malignant tumors. They cause symptoms by local growth causing nerve compression and sometimes by bone destruction. Benign tumors can often be cured by complete surgical removal. However they can grow back if not removed completely.