

Brain Trauma

Skull Fractures

Skull fractures are described as simple, comminuted (multiple pieces), closed, open (also called compound, meaning a fracture in contact with the outside world or an air sinus), depressed, and whether or not they involve the skull base. Skull base fractures can cause injury to cranial nerves, arteries and veins, and can result in CSF leak from the nose or ear. Most skull fractures do not require surgery. In general, fractures that might require surgery are those that are depressed and/or require repair of CSF leak.

Brain Contusion

Brain contusions are “bruises” of the brain that occur when the brain moves quickly forward and then backward with head trauma. Brain contusions thus occur at the site of impact and the side opposite to impact, a phenomenon known as “coup/contra-coup” injury. Large brain contusions resulting in large hematomas of the brain may require surgery. Most do not.

Penetrating Trauma

Penetrating trauma to the brain (e.g. gunshot wound) results in injury to all layers of the skull, dura and brain, and may require surgery for subdural or epidural hematoma, brain hematoma, compound depressed fracture, or other reasons.

Subdural and Epidural Hematoma

Subdural hematoma is relatively common in the elderly population. A blow to the head can result in tearing of veins that bridge from the brain to the dura. Patients on Coumadin or Plavix are at particular risk. Since the skull is a closed space, any amount intracranial bleeding causes some degree of increased intracranial pressure. The brain can shift and accommodate a certain amount of hematoma. However as pressure increases, surgery becomes increasingly necessary. Some subdural hematomas are very small initially, but continue to bleed slowly over time, increasing their volume. Thus, subdural hematomas can be acute, subacute or chronic, and small or large. Subdural hematomas may or may not be a neurosurgical emergency.

Epidural hematomas are relatively rare. Most epidural hematomas are seen with skull fractures involving the temporal bone (side of the head) where the fracture tears the middle

meningeal artery of the dura. This results in bleeding under arterial pressure that dissects the dura away from the inner surface of the skull, forming a large hematoma. Most epidural hematomas are a neurosurgical emergency.

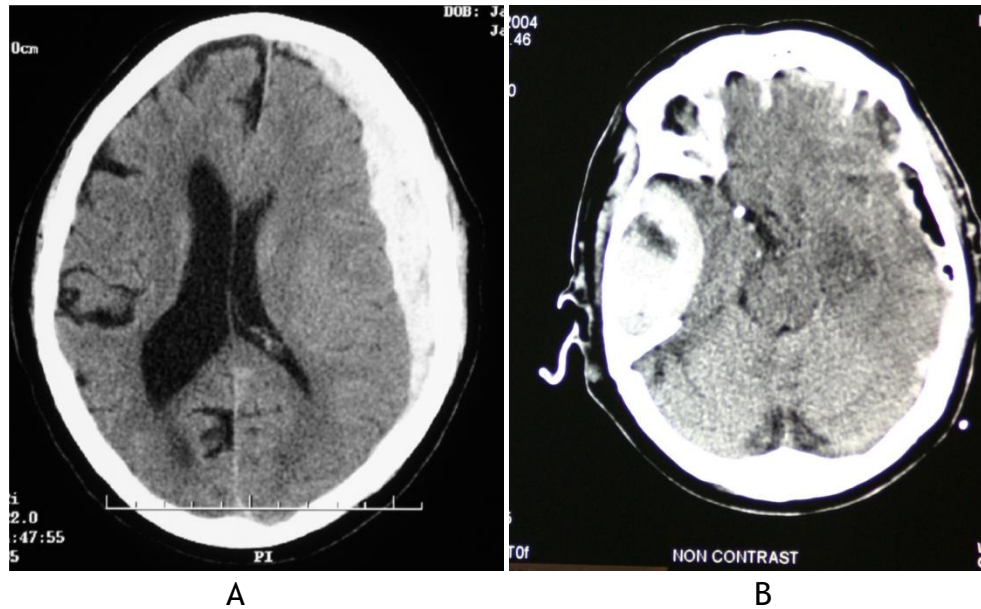


Figure 12: Subdural and Epidural Hematoma

- A. Acute subdural hematoma with mass effect and midline shift.
- B. Acute epidural hematoma of the temporal fossa with mass effect.