

## Benign Spine Disease

### Spinal Stenosis and Degenerative Spine Disease

**Degenerative spine disease** is a more or less global process that can be thought of as a wearing-out of the spine. It usually occurs slowly, but in some people it can be seen at a young age. It is the same type of disease process that occurs with all the joints of the body, such as knees, hips and shoulders (Figure 2).

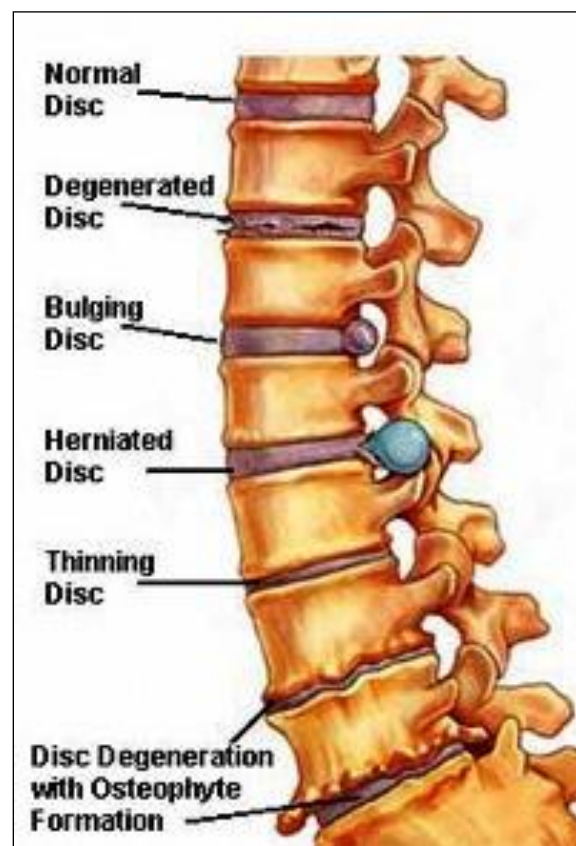


Figure 2: Degenerative Spine Disease and Herniated Disc

Degenerative spine disease goes by many names, such as degenerative disc disease, degenerative joint disease of the spine, spinal arthritis/osteoarthritis and spondylosis. In degenerative spine disease there is facet joint inflammation, disc inflammation, disc bulging, buckling of the ligaments, **osteophyte** formation (growth of bone spurs), and spinal deformity. These processes can lead to nerve compression. The term **spinal stenosis** refers to this type of process (“stenosis” means “constriction”). Spinal stenosis can occur

within the spinal canal, referred to as central spinal stenosis, or in the neural foramina, referred to as foraminal stenosis (Figure 3).

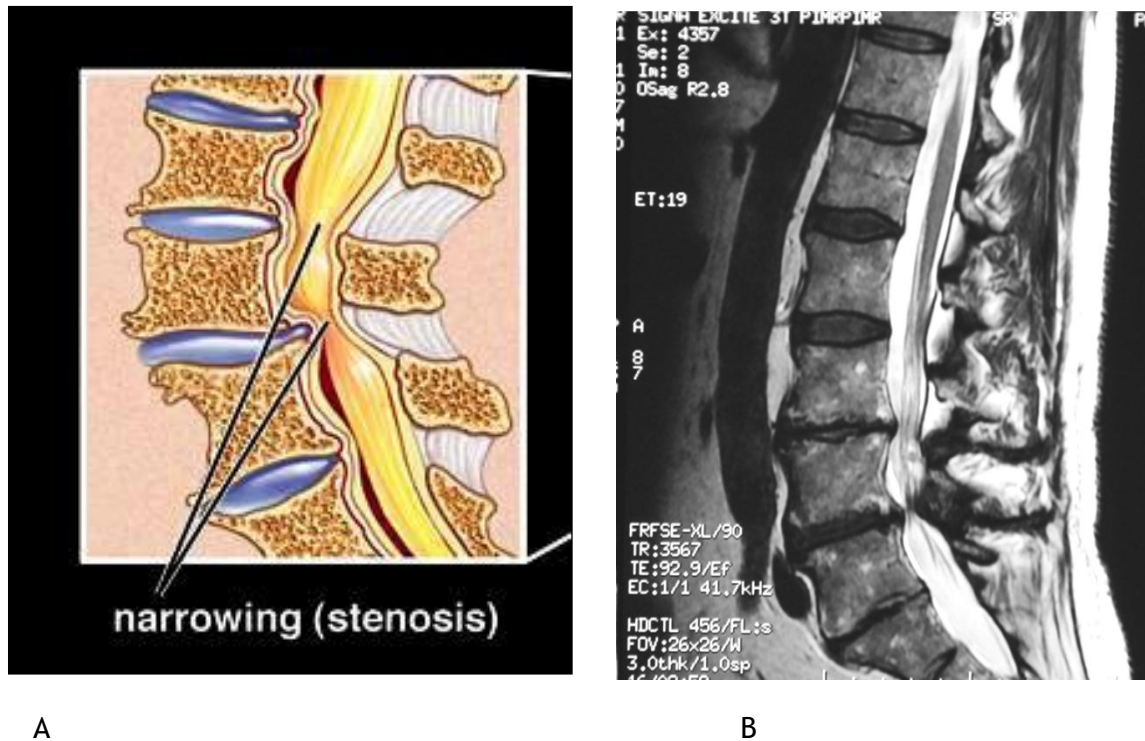


Figure 3: Spinal Stenosis  
A: Drawing, sagittal view from the left side.  
B: MRI, same orientation.

Occasionally, a spinal disc, itself, may cause pain as it degenerates due to annular tears, bulging, or inflammation. This is called **discogenic pain** and it is distinguished from pain due to nerve compression.

When there is a slight tear in the disc annulus and the nucleus starts to push into the tear, this can cause pain. This is called an **annular tear**. It is conceptually slightly different from disc herniation because the nucleus is generally intact and full. Most annular tears are not painful.