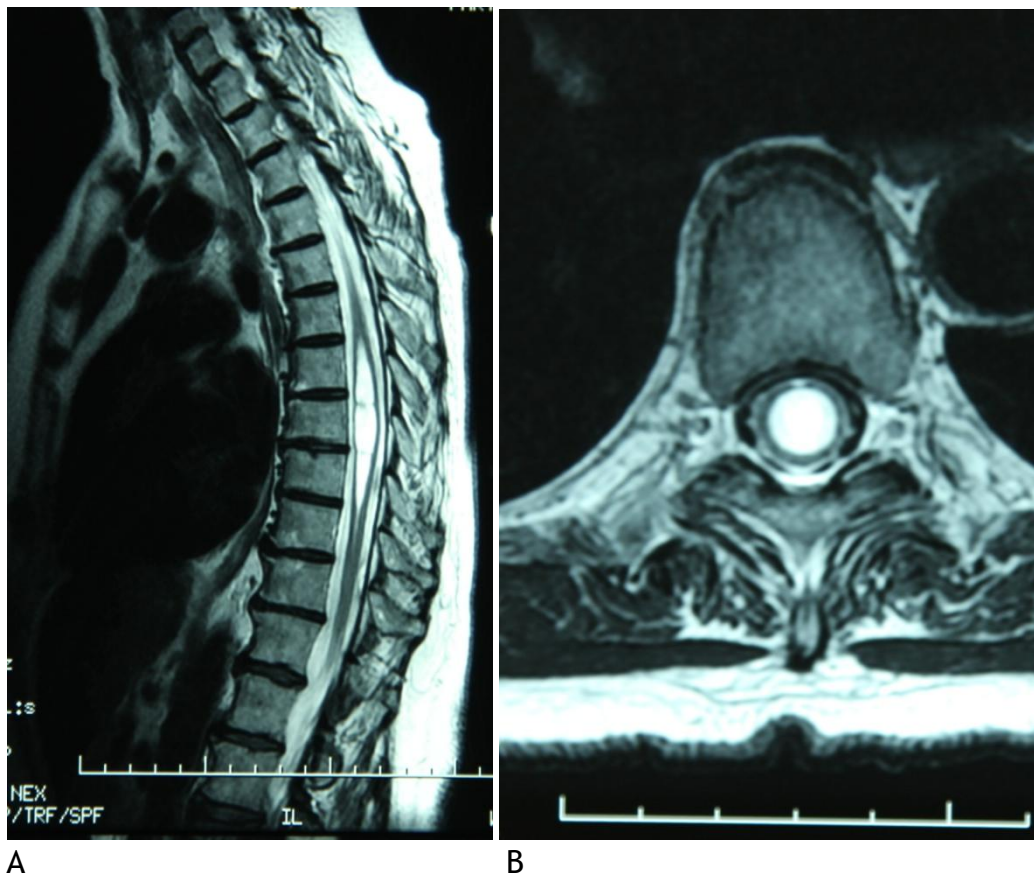


## Syrinx

A syrinx, also called syringomyelia, is a fluid cavity that develops in the spinal cord. Many small syrinxes are seen on MRI scans and have no symptoms. If a syrinx becomes large, it causes symptoms due to pressure from inside the spinal cord.

Syrinxes are frequently seen in cases of Chiari malformations and spina bifida. They are also seen with spinal cord tumors and trauma.



A

B

Figure 11: Spinal cord syrinx (white), mid thoracic spine.

A. Sagittal view, thoracic spine MRI. Note septations (webs) in syrinx cavity.

B. Axial view. Note large size of syrinx cavity.